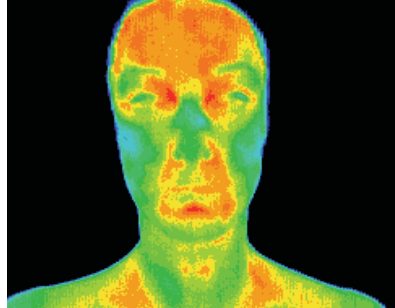
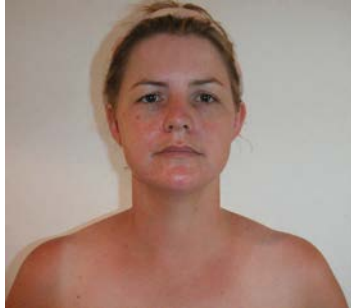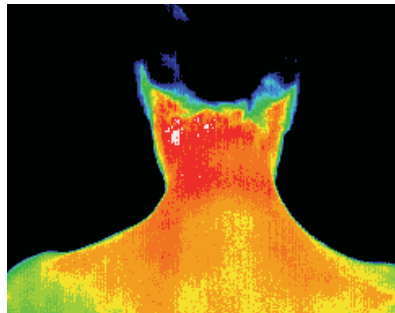

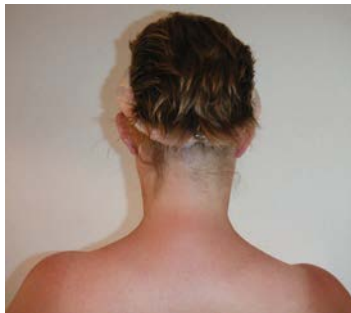
HEAD-VIEWS & FILE NAMING PROTOCOL

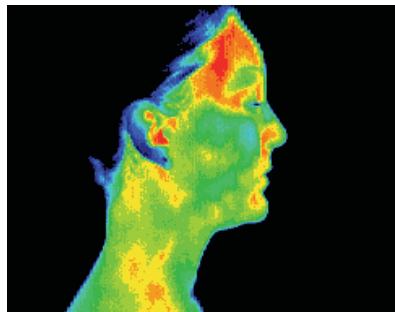
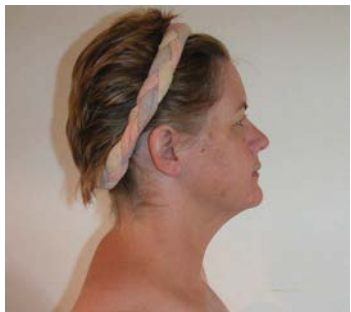A1



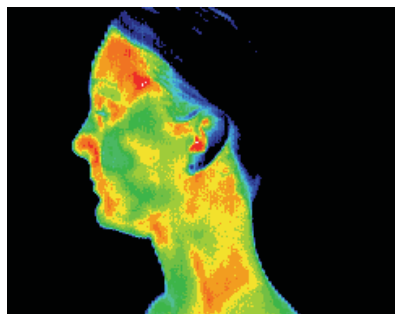
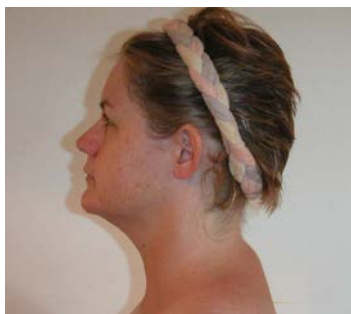A1A (Anterior)



A1P (Posterior) or
A1C (Cervical)

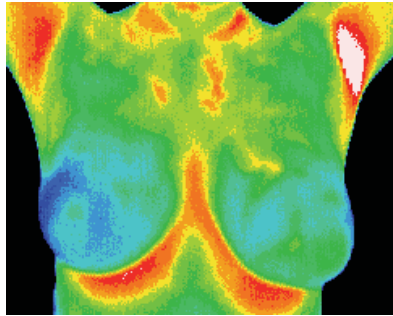
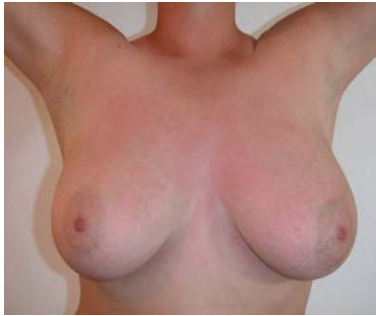

A1LR (Lateral Right)



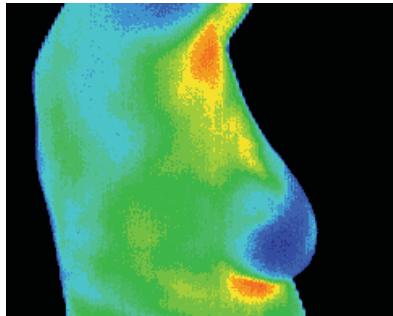
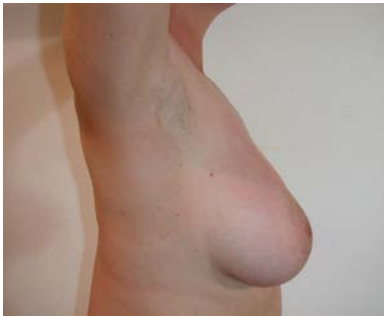A1LL (Lateral Left)

BREAST—VIEWS & FILE NAMING PROTOCOL

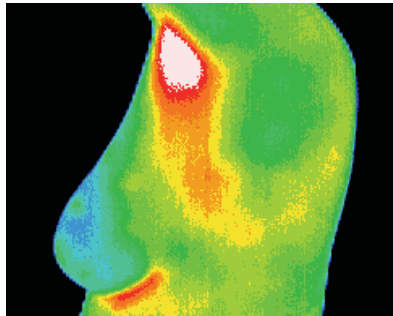
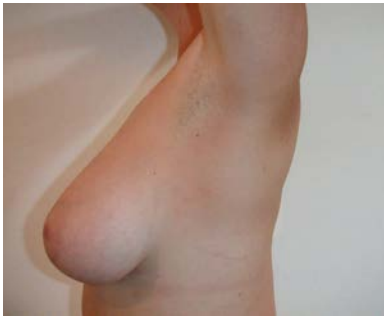

A2B

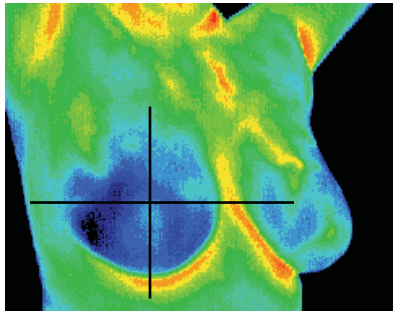
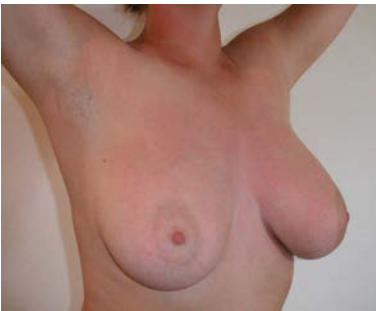A2BA (Anterior)



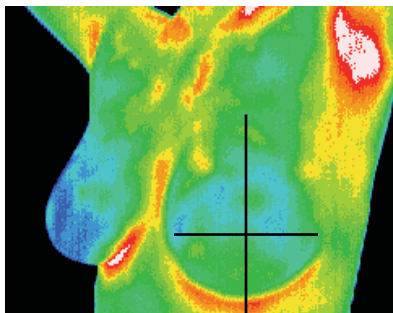
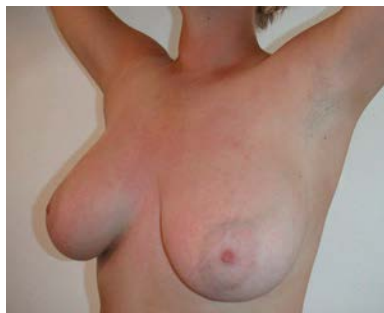A2BLR (Lateral Right)



A2BLL (Lateral Left)

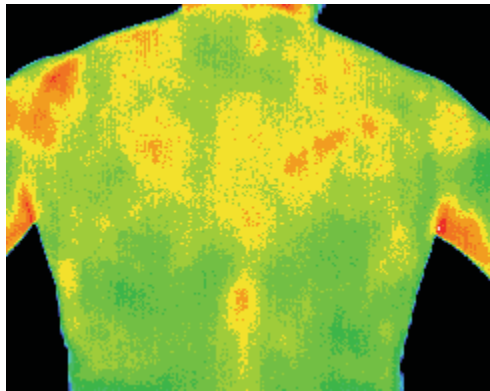


A2BOR (Oblique Right)



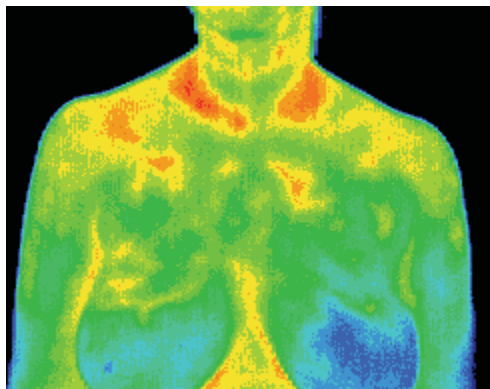
A2BOL (Oblique Left)

ADDITIONAL A2 VIEWS



A2P (Posterior)

Note Arms down
(anatomical position)

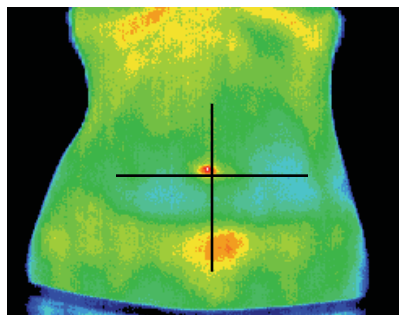
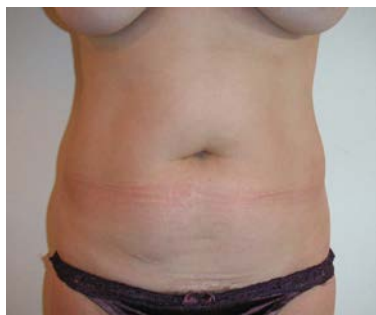

A2A (Anterior)

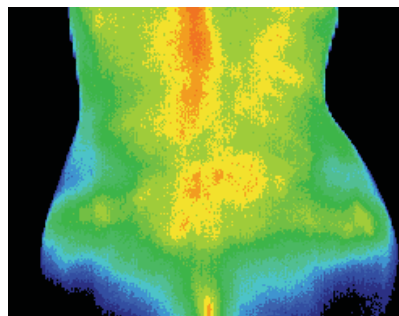
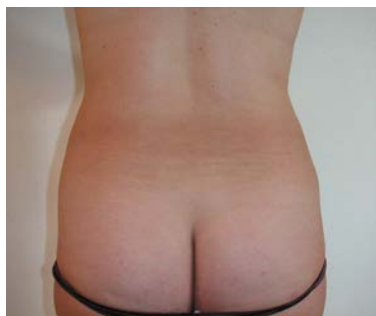
Use these views in addition to breast studies when there are complaints related to the shoulders. These are also useful views for heart patterns.

ABDOMEN-VIEWS & FILE NAMING PROTOCOL

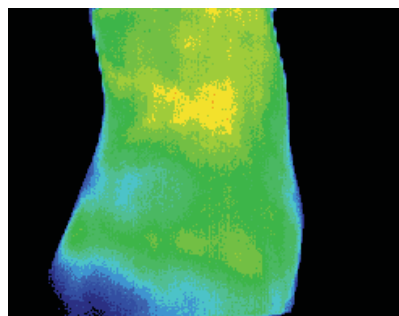

A3



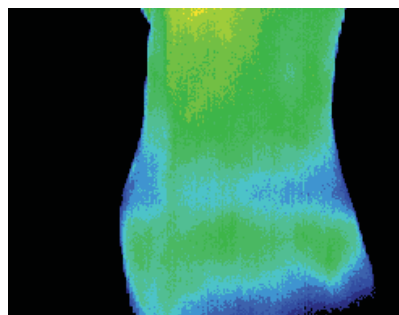
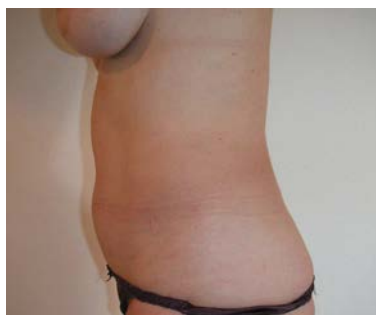
A3A (Anterior)



A3P (Posterior)



A3LR (Lateral Right)



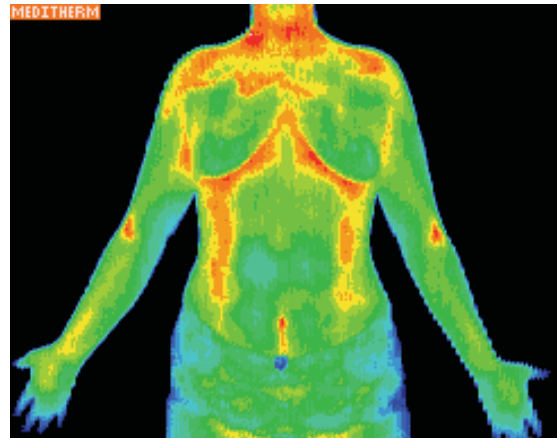
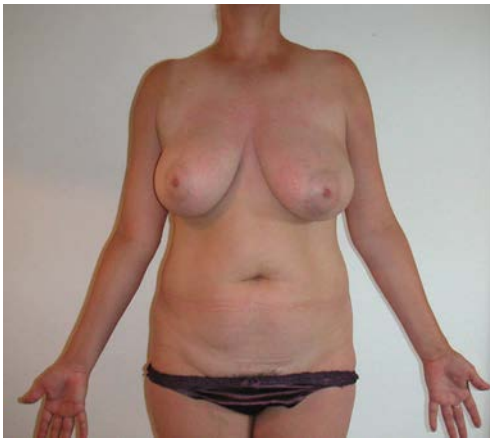A3LL (Lateral Left)

TRUNK-VIEWS & FILE NAMING PROTOCOL

A

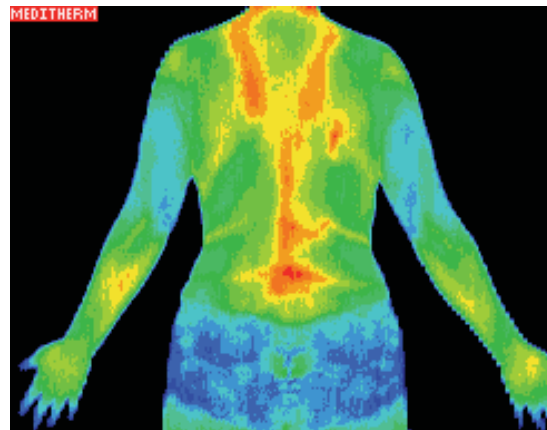
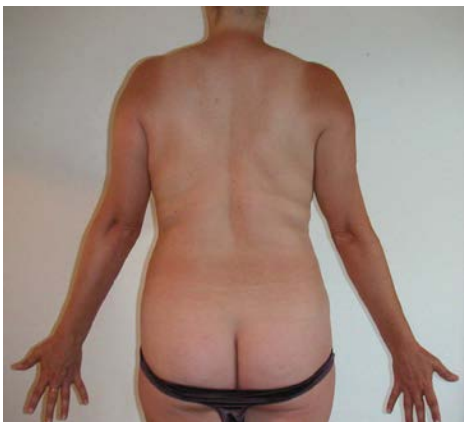
AA (Anterior)

Male & Female



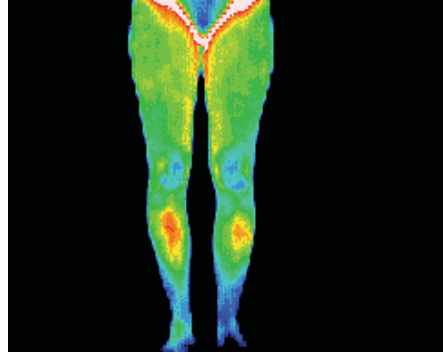
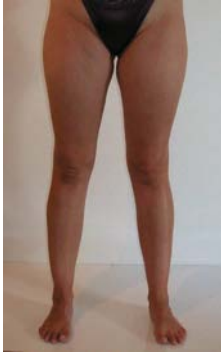AP (Posterior)

Male & Female

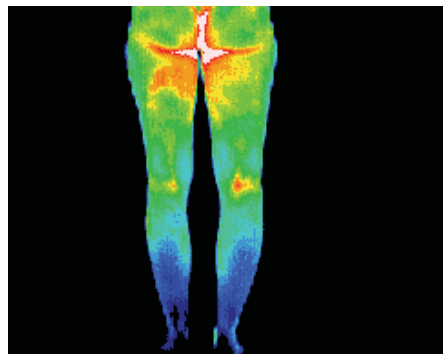
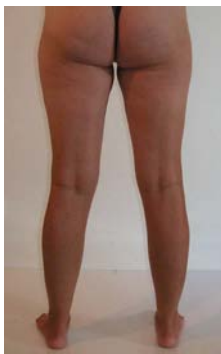

LEGS-VIEWS & FILE NAMING PROTOCOL

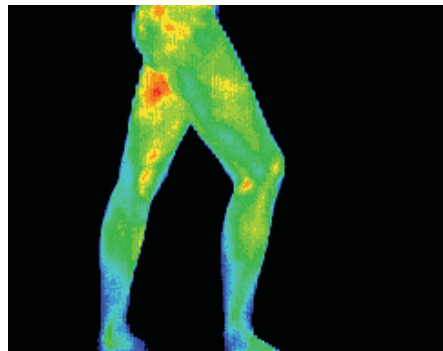
L



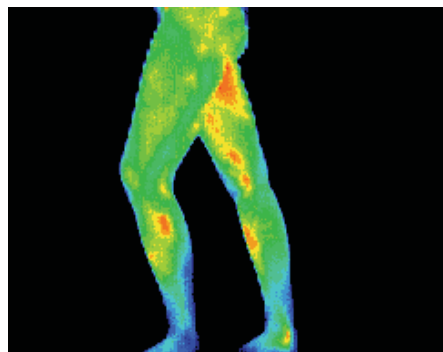
LA (Anterior)



LP (Posterior)

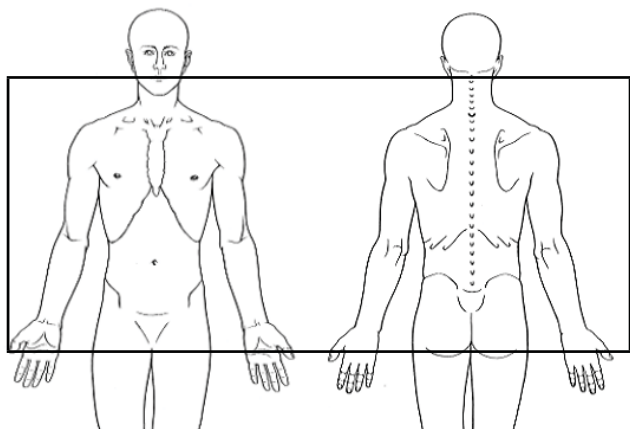


LLR (Lateral Right)



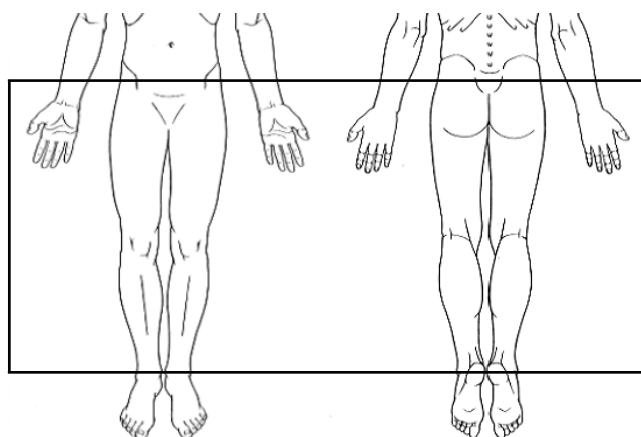
LLL (Lateral Left)

Standard Region of Interest views for Thermographic studies



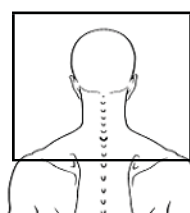
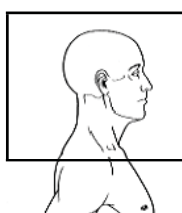
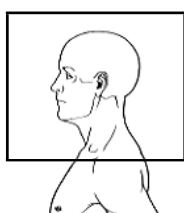
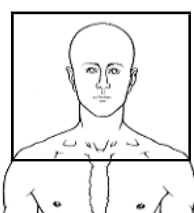
A. Trunk

A general overview of the upper body not including the head. Normally only anterior and posterior views are taken in this view.

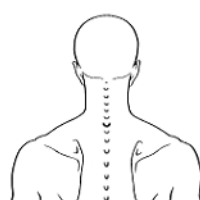
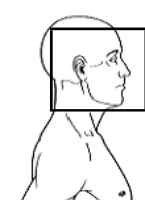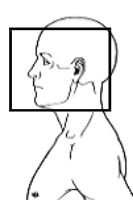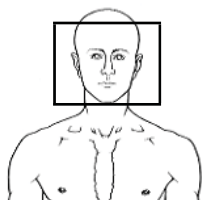


B – Lower Body

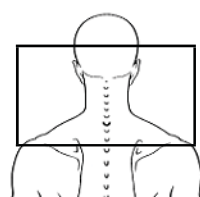
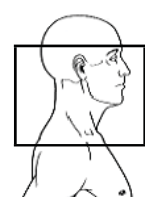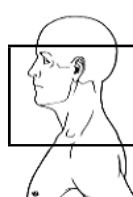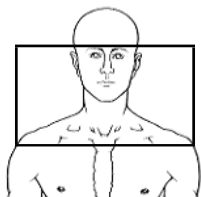
A general overview of the lower body. Normally only anterior and posterior shots are taken in this general view.



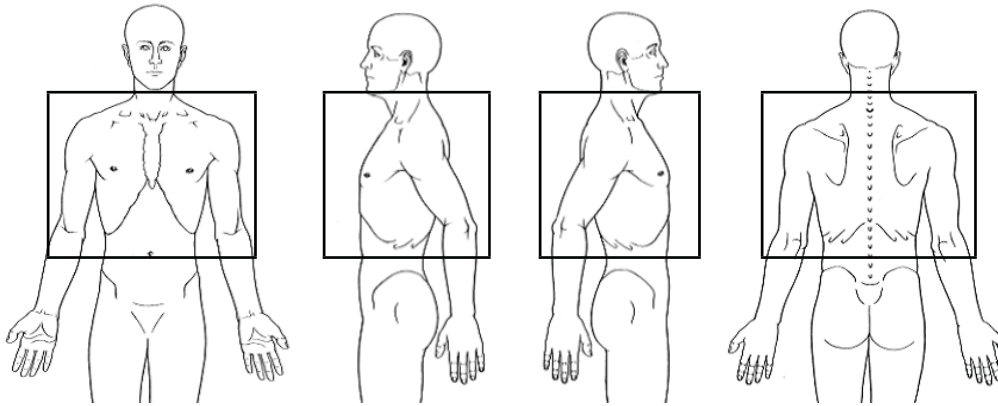
A1: UPPER AXIAL.
Superior head to inferior clavicle / T3.



A1F: FACE.
Superior hairline to inferior chin

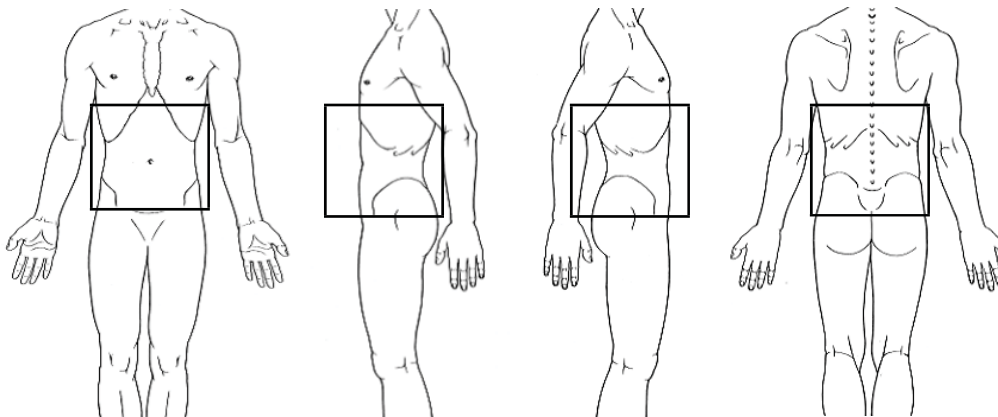


A1C: CERVICAL
Mid cranium to inferior clavicle / T3



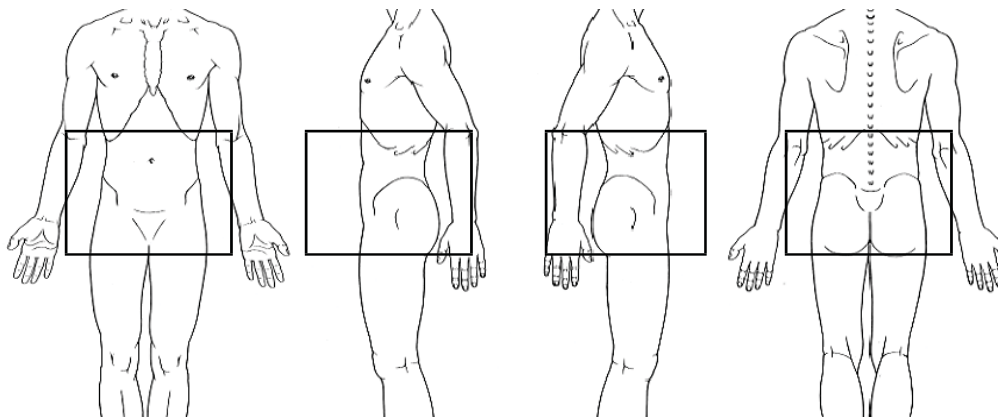
A2 : MID AXIAL

Inferior chin to
L3 / Umbilicus.



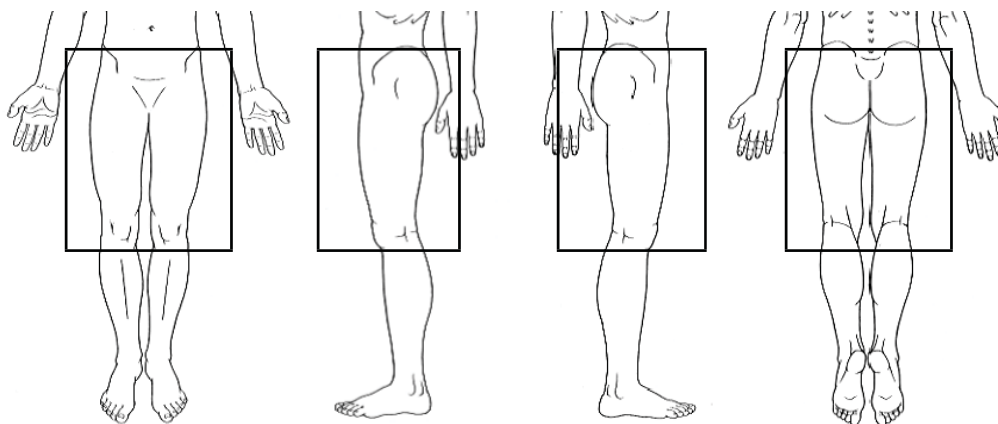
A3 : INFERIOR AXIAL

T12 to proximal
thigh



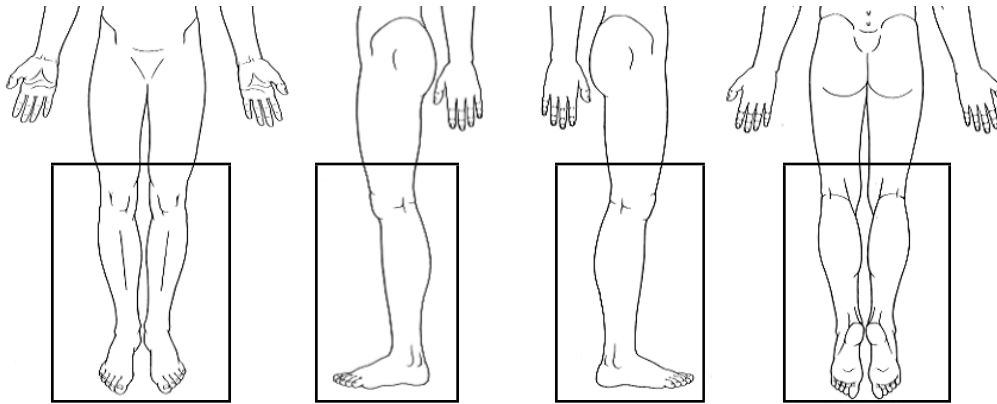
A3L : LUMBAR

T12 to gluteal
crease

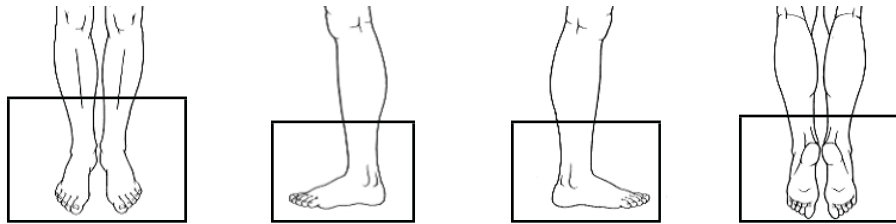


L1 : PROXIMAL LEG

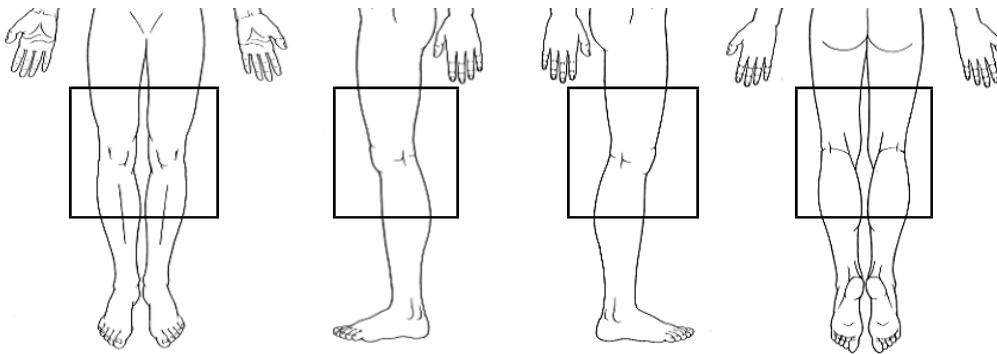
Proximal Hip to
distal knee

**L2 : DISTAL LEG**

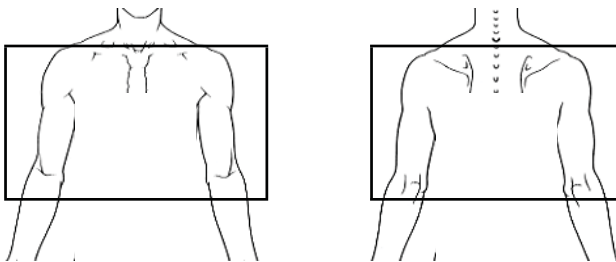
Proximal knee to distal foot.

**L3 : FOOT**

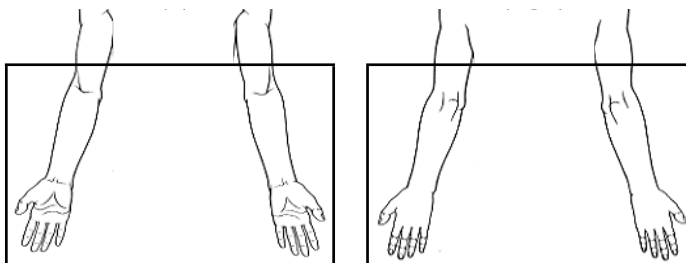
Proximal ankle to distal foot.
Include medial & plantar views.

**L4 : Knee**

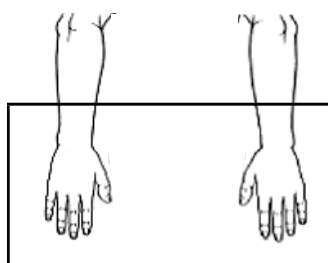
Mid thigh to mid shin.
Include medial views.

**B1 : PROXIMAL ARM**

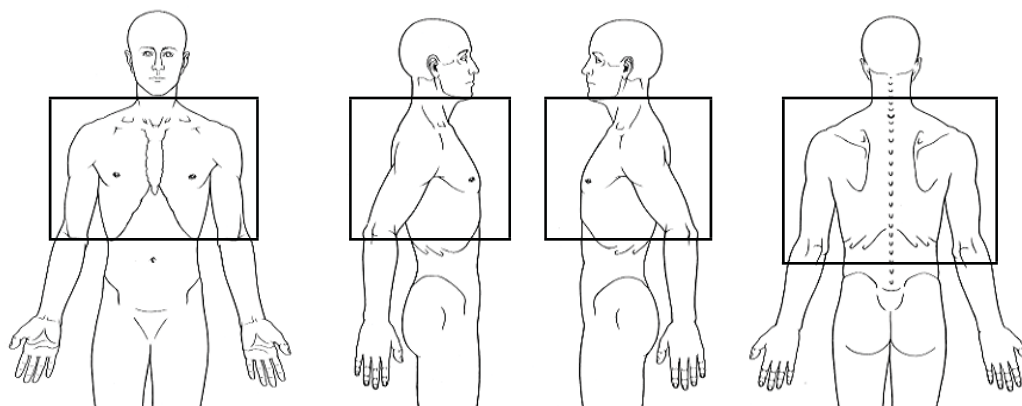
AC joint to distal elbow.
Include lateral views

**B2 : DISTAL ARM**

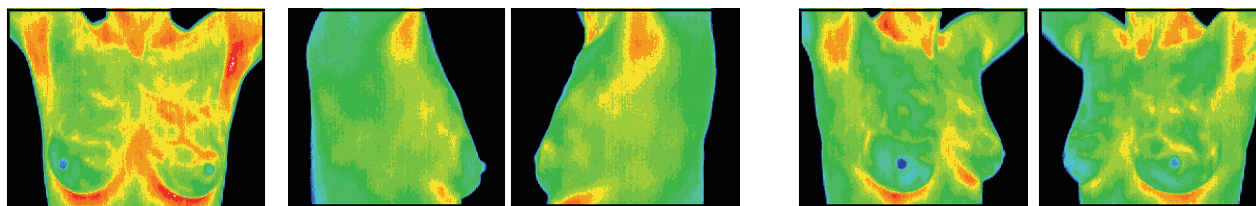
Proximal elbow to distal phalanx.
Include lateral with elbow in flexion

**B3 : HAND**

Distal forearm to distal phalanx.
Include both palmar & dorsal views
with fingers parted.



A2B : Breast
 Inferior chin to
 1inch inferior to
 breast. Include
 both anterior /
 oblique views.
 Posterior view at
 discretion.



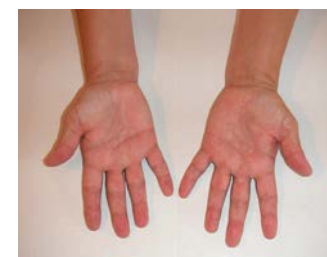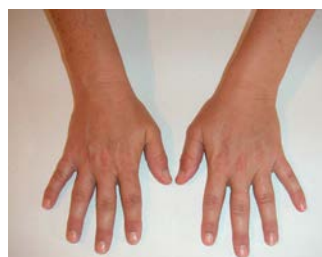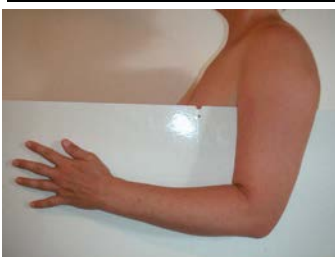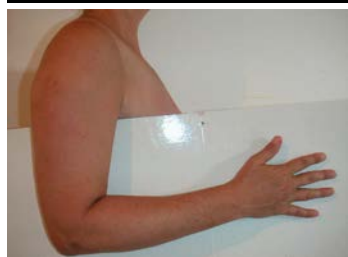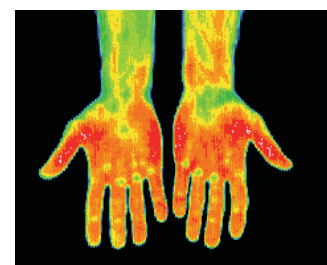
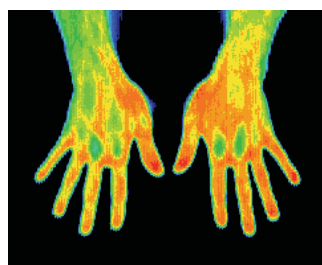
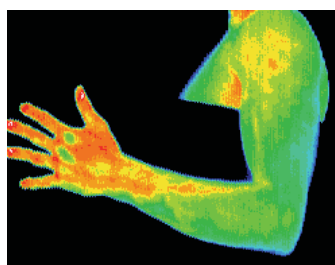
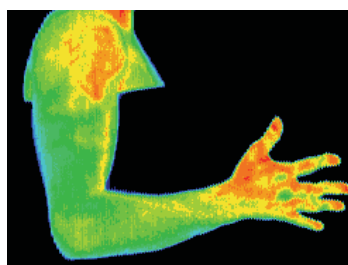
Special Studies

Arms: BLR

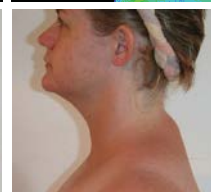
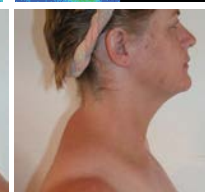
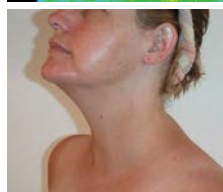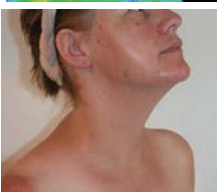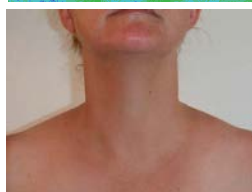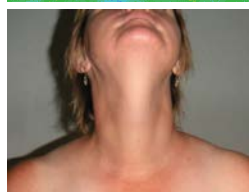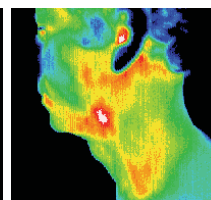
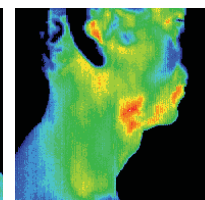
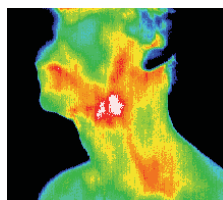
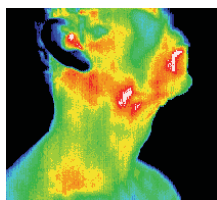
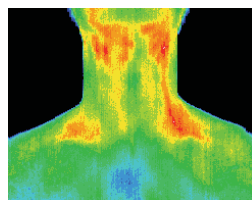
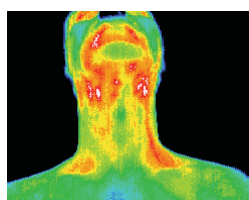
BLL

Hands: B3D

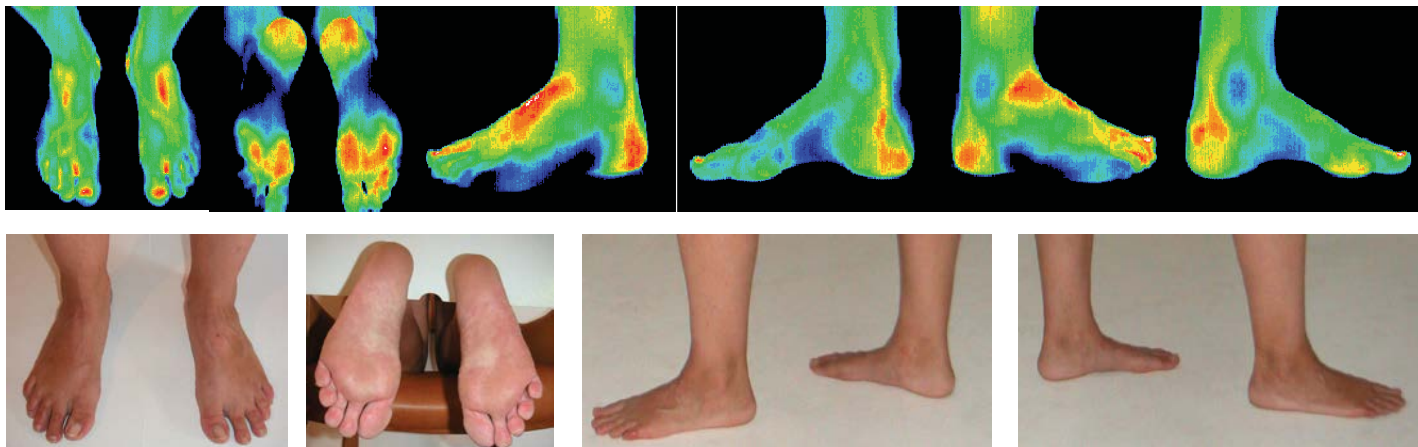
B3P



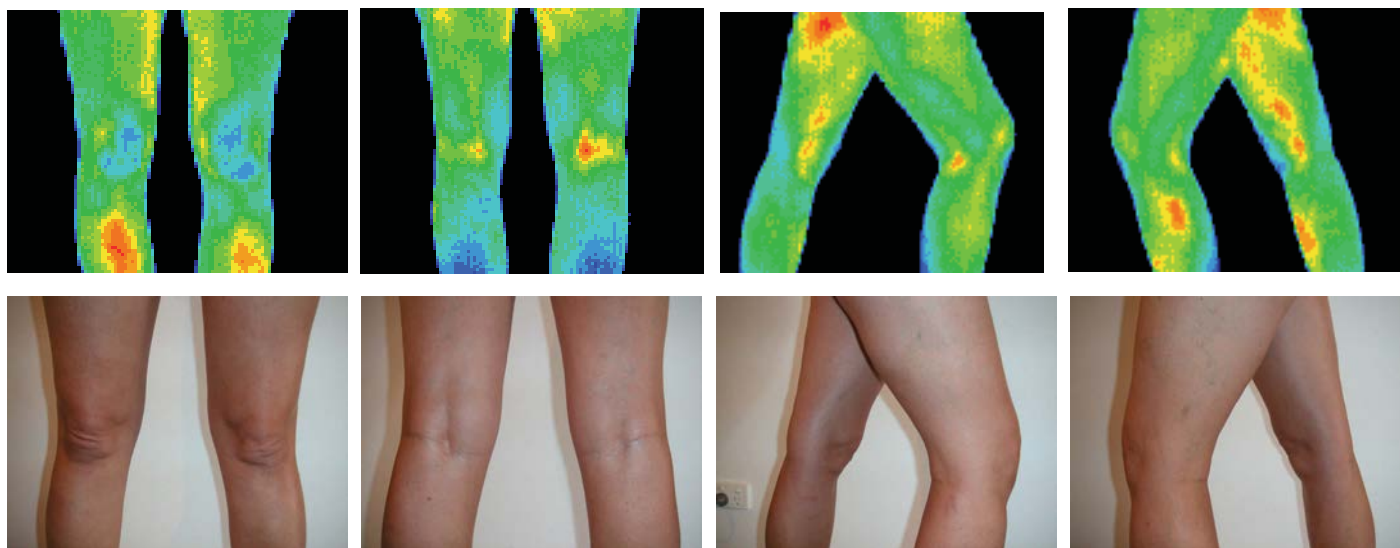
Thyroid / Digastric region / Carotid



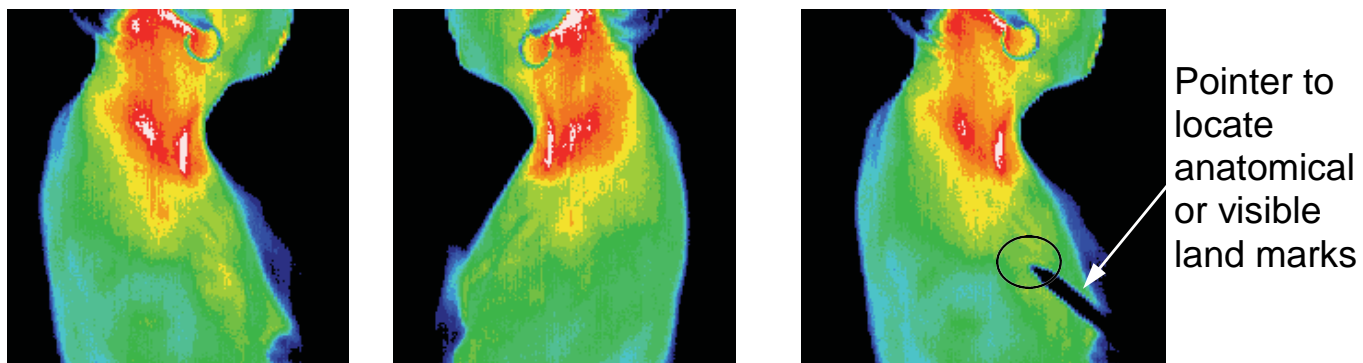
Feet L3



Knees L4



Dorsal Shoulders



STANDARD FULL BODY VIEWS WITHOUT THE BREAST

